

Volkova O.K.^{1,3}, Kalina A.V.², Karpovich G.S.², Volkov I.V.³

¹City Children's Clinical Emergency Hospital, Novosibirsk, Russia;

²Novosibirsk State Medical University, Ministry of Health of Russia, Novosibirsk, Russia;

³Sibneiromed City Neurology Center, Novosibirsk, Russia

¹3, Krasnyi Prospect, Novosibirsk 630007; ²52, Krasnyi Prospect, Novosibirsk 630091; ³37, Michurin St., Novosibirsk 630091

Nonepileptic myoclonus of infancy and early childhood (an observation of 33 patients)

Fejerman syndrome, a benign nonepileptic myoclonus of infancy (BNMI), is a rare type of paroxysmal events, which mimics epileptic spasms. It is difficult to determine the nature of myoclonus without video electroencephalography (VEEG) monitoring.

Objective: to present the clinical and electroencephalographic characteristics of new cases of benign nonepileptic myoclonus of infancy and early childhood.

Patients and methods. The data of 33 children (19 boys and 14 girls) aged 5 months to 3 years with BNMI, who had been followed in 2011 to 2017, were analyzed.

Results and discussion. The age at onset of paroxysms ranged from 4 to 24 months and that was 5–8 months in most cases. The most common movements were extensor muscle jerks (30.3%), head titubation with rotation (27.3%), axial spasms (27.3%), and nods (24.2%). The same child may have different types of paroxysms. Motor paroxysms were sporadic in all the patients and formed into clusters in 33.3% of cases. The frequency of clusters was up to 10 times daily. There were 2 to 50 paroxysms in the cluster. There was delayed psychomotor development in 5 of the 33 children and hyperexcitability was present in 10. VEEG monitoring indicated that the brain bioelectrical activity conformed to the age in 97% of cases; none of the children showed abnormal movements accompanied by EEG pathological activity. The duration of the disease was 2 to 19 months, averaging 7 months. In all cases paroxysms were stopped without using antiepileptic drugs.

Conclusion. It is extremely important to timely recognize BNMI, since anti-epileptic therapy can be unreasonably prescribed in cases of an erroneous diagnosis. VEEG monitoring plays a crucial role in diagnosing nonepileptic and epileptic myoclonus.

Keywords: benign nonepileptic myoclonus of infancy and early childhood; Fejerman syndrome.

Contact: Iosif Vyacheslavovich Volkov; viv114476@mail.ru

For reference: Volkova OK, Kalina AV, Karpovich GS, Volkov IV. Nonepileptic myoclonus of infancy or early childhood (an observation of 33 patients). *Nevrologiya, neiropsikhiatriya, psikhosomatika = Neurology, Neuropsychiatry, Psychosomatics.* 2019;11(2):42–45.

DOI: 10.14412/2074-2711-2019-2-42-45

Paroxysmal movements disorders are a common reason for consulting a pediatric neurologist. The most common form of such disorders is myoclonia + sudden short abrupt movements in the muscles of the limbs, trunk, face, not accompanied by loss of consciousness [1]. Myoclonus can occur in one or different groups of muscles, body segments or it can be generalized. There are physiological, idiopathic, symptomatic and epileptic myoclonus. Sometimes it is very difficult to draw the border between epileptic and non-epileptic myoclonus [2]. Electroencephalography (EEG) including Video-EEG monitoring (VEEG) is used for diagnostic.

Fejerman+s syndrome + is a benign non-epileptic myoclonus of early infancy (BMEI) + is a relatively rare type of paroxysmal non-epileptic phenomena, in appearance indistinguishable from epileptic seizures, such as infantile spasms or myoclonic seizures. The study of this syndrome is an important issue, because the correct diagnosis helps to prevent the prescription of antiepileptic and even hormonal therapy to healthy infants due to an incorrect diagnosis [3]. The aetiology of Fejerman+s syndrome is unknown [4]. B. V. Maydell et al. [5] described motor manifestations of the syndrome as an exalted physiological myoclonus. Benign myoclonus usually occurs during the first year of life and spontaneously stops by the age of 2–3 [6].

Objective: to present the clinical and electroencephalographic characteristics of new cases of benign non-epileptic myoclonus of infancy and early childhood.

Materials and methods. 33 patients (19 boys and 14 girls) with BMEI aged from five months to three years (mean age 14+1,2 months) were followed up in the consultative neurological department of the State Budgetary Healthcare Institution Children's Clinical Emergency Hospital of Novosibirsk from 2011 to 2017. The duration of the disease ranged from two to nineteen months (average 7 months). More than half of the children had a burdened obstetric history.

The criteria for inclusion in the study were the criteria for the diagnosis of non-epileptic myoclonus of infancy and early childhood defined in 1977 [6]:

- onset of motor paroxysms in the first year of life;
- self-occupation, variable duration of the disease within the age of 2;
- psychomotor development corresponding to the age norm;
- no epileptic seizures;
- no signs of epileptiform activity on EEG;
- the paroxysm during wakefulness, associated with emotional stimuli;
- no effect of antiepileptic drugs.

Exclusion criteria: presence of motor paroxysms, accompanied by epileptiform discharges on EEG.

The data of anamnesis, the main clinical manifestations, neurological status, as well as the results of instrumental methods of research, in particular VEEG, were analyzed.

For statistical analysis we used descriptive statistics: we calculated the average and standard error of the average (data are presented in the form of M±m) for quantitative variables, for qualitative variables we determined percentage.

Results. The age of the onset of the paroxysm is shown in Fig.

Clinical manifestations of motor phenomena are shown in table 1.

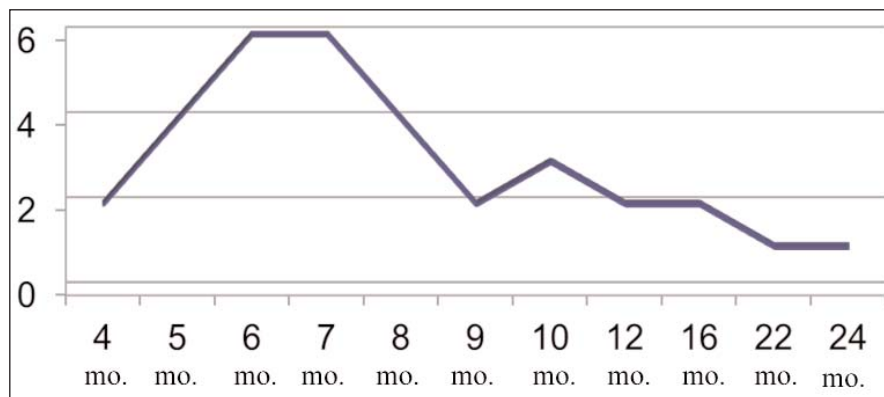
Motor paroxysms were single for all patients and were formed into clusters in 11 (33.3%) of 33 cases. The frequency of clusters + up to 10 times a day, the number of paroxysms in the cluster + from 2 to 50. The distribution of paroxysms during the day is presented in table. 2.

A burdened obstetric history was present in 20 (60.6%) of 33 cases. Changes in neurological status in the form of muscle tone disorders (by type of hypotension) were found in 19 (57.6%) children. The mild delay in the psychomotor development was observed in 5 (15.2%) patients, hyperexcitability syndrome + in 10 (30.3%).

In VEEG, the bioelectric activity of the brain was appropriate for the age in 97% of cases, abnormal movements were not accompanied by pathological activity on EEG in all cases under study. In all patients, paroxysms were stopped without the use of antiepileptic drugs.

Discussion. BMEI is a rare syndrome. In the first N. Fejerman+s report, published in 1976 [7], 10 patients with a clinical manifestation similar to West+s syndrome were described, but they had no psychomotor development disorders and normal EEG results. Several years later, European authors published observations of BMEI [8–10]. In 1999 S. Pachatz et al. [11] presented 5 more similar cases with the results of VEEG. By 2002, N. Fejerman and R. Caraballo [12] had described more than 40 patients with BMEI tracking their catamnesis. The final work was an article published in 2009 by R. H. Coraballo et al. [6], which presents data of 102 patients from the Argentine cohort and two Italian centers. Russian authors described two clinical cases of Fajerman+s syndrome [4]. Therefore, BMEI is relatively rare. We present a description of 33 clinical cases revealed while consulting a pediatric epileptologist in Novosibirsk, but these data are not enough to determine the true prevalence of BMEI.

In the group we observed, the age of motor paroxysm onset varied from 4 to 24 months, amounting in most cases to 5–



The age of the onset of paroxysms

Table 1. Clinical manifestations of motor phenomena.

Movement	The number of the patients, n (%)
Jerkings in extensor muscles	10 (30,3)
Shuddering in head and neck with rotation	9 (27,3)
Axial spasms	9 (27,3)
Nods	8 (24,2)
Grimaces	5 (15,2)
Tonic flexion of limbs	5 (15,2)
Lower limb involvement	3 (9)
Lifting of the shoulders	2 (6,1)
Clenching of the fists	1 (3)

Table 2. The distribution of paroxysms during the day.

The time of occurrence of the paroxysms	The number of the patients, n (%)
During wakefulness	25 (75,6)
When falling asleep	8 (24,2)
On waking	6 (18,2)
During sleep	4 (12,1)

8 months, which corresponds to the data of other authors [6, 13] on the occurrence of non-epileptic myoclonus in the first year of life.

Motor manifestations of BMEI are various. In the first report N. Fejerman described a clinical picture resembling the West's syndrome: nods or short shudders similar to infantile spasms [7]. Motor phenomena including myoclonic jerks, spasms, short tonic contractions and shuddering were observed in the European cohort [14]. Shuddering are also described by O. Kanazava [15]. R. H. Caraballo et al. [6], considering the clinical picture of paroxysms and their correlation with the ictal polygraphic recording with muscle electrodes, proposed to divide all motor manifestations of BMEI into four groups: myoclonus; shuddering paroxysms; spasms with short-term tonic tension of the limbs and/or head and neck; atony. We did not use this division but found that in our patients the most frequent movements were: jerkings in extensor muscles (30.3%), shuddering in head and neck with rotation (27.3%), axial spasms (27.3%) and nods

(24.2%). It should be noted that one child might encounter different types of motor phenomena.

All of our patients had single paroxysms, a third of them had paroxysms formed into clusters of up to 50 episodes, and the clusters themselves were repeated up to 10 times a day. According to R. H. Caraballo et al. [6], series and clusters occurred in 44% of patients causing a long duration of paroxysms. It is also noted that episodes may occur several times a day, but not necessarily daily.

As in the classic description of the syndrome, the paroxysmal movements were recorded during wakefulness [12], but later other authors pointed to the possibility of the occurrence of myoclonus during sleep [6]. In our patients, paroxysmal conditions were also most often recorded during wakefulness (75.6%), but were also encountered when falling asleep (24.2%), on waking (18.2%) and during sleep (12.1%), which broadens the range of differential diagnosis of BMEI. This range includes both severe conditions such as infantile spasms [16] and benign conditions such as myoclonus of falling asleep.

More than half of the children in our study had a burdened obstetric history, and we did not find such data in the works of other authors. It is difficult to judge reliably the impact of this factor on the development of Fejerman+s syndrome. However, approximately the same number of patients in the study of neurological status was found to have muscle hypotension, which is not a focal symptom, and may indicate the presence of concomitant

neurological or somatic pathology. 15.2% of patients had a mild delay in the psychomotor development, 30.3% + hyperexcitability syndrome. In addition, 1 (3%) child's background brain activity did not correspond to the age. The given research reveals that BMEI can develop not only in absolutely healthy children from a neurological point of view. C. Canavese et al. [17], analyzed paroxysmal non-epileptic motor paroxysms in childhood, indicate that BMEI may occur in children with neurological disorders.

According to the criteria of the diagnosis of Fejerman+s syndrome, motor paroxysms were not accompanied by pathological activity during VEEG [6]. This feature is crucial in the differential diagnosis of non-epileptic and epileptic myoclonus.

Fejerman+s syndrome independently stopped in all patients for an average of 7 months (from 2 to 19 months) without the use of antiepileptic drugs, which confirms its age-dependent nature and benignity.

Conclusion. Therefore, non-epileptic myoclonus is a benign age-dependent self-bringing syndrome. Its timely recognition is extremely important, as in cases of hyperdiagnosis may be unreasonable prescription of antiepileptic therapy, in addition, there is a risk of further social stigmatization of patients. Insufficient diagnostics is dangerous because epileptic syndromes cannot be identified, which without the prescription of adequate and timely therapy have an unfavorable prognosis for the development of the child. The major role in the diagnosis of non-epileptic and epileptic myoclonus has VEEG.

R E F E R E N C E S

- Shibaki H, Hallet M. Electrophysiological studies of myoclonus. *Muscle Nerve*. 2005 Feb;31(2):157-74.
- Ермаков АЮ. Неэпилептический и эпилептический миоклонус. В кн.: Белоусова ЕД, Ермаков АЮ, редакторы. Дифференциальный диагноз эпилепсии. Москва: Пульс; 2007. 262 с. [Ermakov AYU. Non-epileptic and epileptic myoclonus. In: Belousova ED, Ermakov AYU, editors. *Differentsial'nyi diagnost epilepsii* [Differential diagnosis of epilepsy]. Moscow: Pul's; 2007. 262 p.]
- Fejerman N. Differential diagnoses of West syndrome. *Rev Neurol*. 2013 Sep 6;57 Suppl 1:S125-8.
- Миронов МБ, Ноговицын ВЮ, Абрамов МО и др. Синдром Фейджермана (доброкачественный неэпилептический миоклонус младенчества). Эпилепсия и пароксизмальные состояния. 2013;5(2):42-6. [Mironov MB, Nogovitsyn VYu, Abramov MO, et al. Fejerman syndrome (benign non-epileptic myoclonus of infancy). *Epilepsiya i paroksizmal'nye sostoyaniya*. 2013;5(2):42-6. (In Russ.)].
- Maydell BV, Berenson F, Rothner AD et al. Benign myoclonus of early infancy: an imitator of West's syndrome. *J Child Neurol*. 2001 Feb;16(2):109-12.
- Caraballo RH, Capovilla G, Vigeveno F, et al. The spectrum of benign myoclonus of early infancy: Clinical and neurophysiologic features in 102 patients. *Epilepsia*. 2009 May;50(5):1176-83. doi: 10.1111/j.1528-1167.2008.01994.x. Epub 2009 Jan 19.
- Fejerman N. Mioclonias benignas de la infancia temprana. Comunicacion preliminar. Actas IV Jornadas Rioplatenses de Neurologia Infantil. Neuropediatria Latinoamericana Montevideo: Delta; 1976. P. 131-4.
- Giraud N. Les spasmes infantiles benignes non epileptiques. *These pour le Doctorat en Medecine*. Marseille; 1982.
- Gobbi G, Dravet C, Bureau M, et al. Les spasmes benignes du nourrisson (syndrome de Lombroso et Fejerman). *Boll. Lega Italiana contro L'Epilepsia*. 1982;39/S:17.
- Dravet C, Giraud N, Bureau M, et al. Benign myoclonus of early infancy or benign non epileptic infantile spasms. *Neuropediatrics*. 1986 Feb;17(1):33-8.
- Pachatz C, Fusco L, Vigeveno F. Benign myoclonus of early infancy. *Epileptic Disord*. 1999 Mar;1(1):57-61.
- Fejerman N, Caraballo R. Appendix to «Shuddering and benign myoclonus of early infancy» (Pachatz C, Fusco L, Vigeveno F). In: Guerrini R, Aicardi S, Andermann F, Hallet M, editors. *Epilepsy and movement disorders*. Cambridge: Cambridge University Press; 2002. P. 343-51.
- Panayiotopoulos C. A Clinical Guide to Epileptic Syndromes and their Treatment. Springer; 2010. P. 112-3.
- Dalla Bernardina B. Benign myoclonus of early infancy or Fejerman syndrome. *Epilepsia*. 2009 May;50(5):1290-2. doi: 10.1111/j.1528-1167.2009.02154.x.
- Kanazawa O. Shuddering attacks - report of four children. *Pediatr Neurol*. 2000 Nov;23(5):421-4.
- Мухин КЮ, Миронов МБ. Эпилептические спазмы: нозологическая характеристика и подходы к терапии. Неврология, нейропсихиатрия, психосоматика. 2013;5(1S):23-8. [Mukhin KYu, Mironov MB. Epileptic spasms: Nosological characteristics and approaches to therapy. *Nevrologiya, neiropsikhiatriya, psikhosomatika = Neurology, Neuropsychiatry, Psychosomatics*. 2013;5(1S):23-8. (In Russ.)]. doi: 10.14412/2074-2711-2013-2484
- Canavese C, Canafoglia L, Costa C, et al. Paroxysmal non-epileptic motor events in childhood: a clinical and video-EEG-polymyographic study. *Dev Med Child Neurol*. 2012 Apr;54(4):334-8. doi: 10.1111/j.1469-8749.2011.04217.x. Epub 2012 Jan 28.

Article received 10.03.2019